

A successful pregnancy following 'double rescue' egg retrieval in a woman with Natural cycle IVF

G. NARGUND, R.-C. CHIAN, S. CAMPBELL

The Centre for Reproduction and Advanced Technology (CREATE Fertility) St Georges House, 3-5 Pepys Road, West Wimbledon, London SW20 8NJ.

Correspondence at: geetanargund@gmail.com

Abstract

A case is reported of a patient with critically low anti-mullerian hormone (AMH) having successful 'rescue' oocyte retrieval in natural in vitro fertilization (IVF) cycle 24 hours after the initial procedure had resulted in no oocyte being collected. Following administration of 10,000 units human chorionic hormone (hCG) a second retrieval was performed 24 hours after the first, producing one Metaphase-I oocyte. After in vitro maturation (IVM) over 4 hours in oocyte maturation medium, intracytoplasmic sperm injection (ICSI) was performed. A subsequent transfer of a 2-cell embryo proceeded on day 2. A positive hCG was recorded 15 days after embryo transfer (ET), and a viable clinical pregnancy has been confirmed. We believe this is the first reported case of a successful egg collection following a prior failed follicle aspiration in Natural IVF cycle. Factors such as good peri-follicular flow and initial follicular fluid cell content are probably essential before attempting a repeat procedure. This report highlights the importance of rescue IVM when an immature oocyte is collected.

Key words: AMH, IVM, natural cycle IVF, oocytes, peri-follicular blood flow.

Introduction

A better understanding of ovarian physiology in relation to ovarian follicular growth and maturation advances in ultrasound technology, the clinical availability of GnRH antagonists and advances in embryology knowledge have allowed the "rediscovery" of natural cycle IVF (Nargund and Frydman, 2007) and have given us the opportunity to make it more successful in day to day practice (Nargund et al., 2001). Several studies have shown that natural cycle IVF has advantages over conventional IVF with down regulation in the management of women with low ovarian reserve (Ata et al., 2008; Schimberni et al., 2009). The case described here concerns a 38 year old woman with low ovarian reserve who was offered natural cycle IVF and who required a second "rescue" of the oocyte following failed initial oocyte collection and also required "rescue" IVM to obtain a mature oocyte for fertilisation.

Case Report

The 38-year-old patient was offered a natural cycle IVF attempt due to critically low ovarian reserve. Her menstrual cycle was regular every 26-28 days and a general examination revealed no abnormalities. Tests prior to treatment were: day 2 FSH 16.4 IU/L, anti-mullerian hormone (AMH) 0.78 pmol/L and antral follicle count (AFC) 3. Her pre-IVF scan showed normal uterine cavity with good uterine artery blood flow (Pulsatility Index = 1.45).

Her partner had a history of bilateral undescended testes resulting in an orchidopexy at the age of 3years. This resulted in his semen analysis showing severe oligoasthenozoospermia. Her first stimulated IVF cycle with ICSI was performed in another clinic in 2007 and resulted in the term birth of healthy female. The second stimulated cycle in January 2010 yielded only one egg which produced a 5 cell embryo on day 2 which was transferred but resulted in a negative pregnancy test. Following this

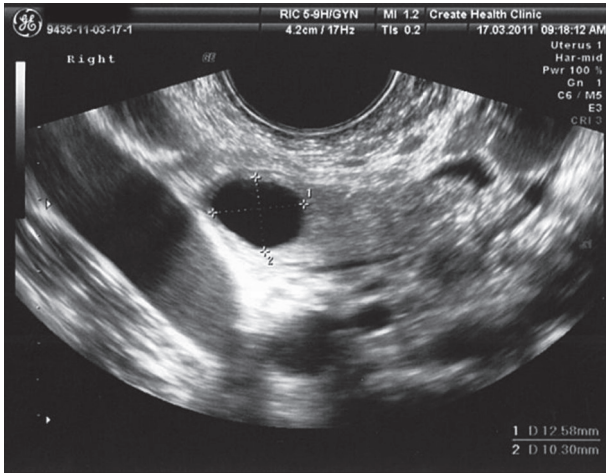


Fig. 1. — Follicle 24 hrs after first egg retrieval attempt

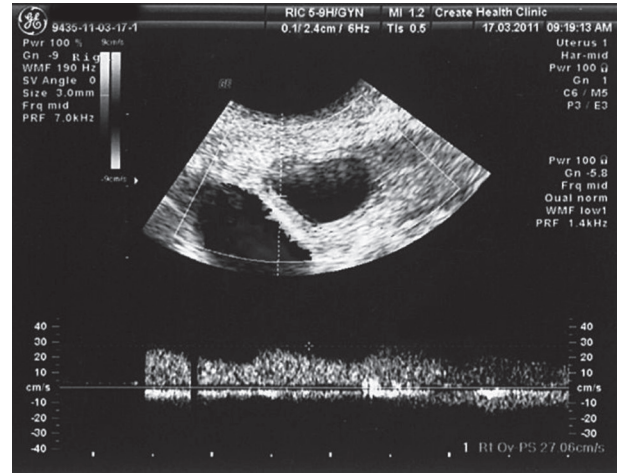


Fig. 2. — Peri-follicular blood flow of the follicle before the second egg retrieval.

attempt and with results showing rising FSH levels (12.3 and 16.4 IU/L) the patient was advised to consider oocyte donation which she did not accept.

In 2011 she attended our clinic for treatment and had 2 unsuccessful Modified Natural IVF cycles. The first produced 2 follicles but no oocyte was retrieved and the second produced 1 oocyte and a 5-cell embryo for transfer but no pregnancy resulted.

In the current cycle the first scan scheduled at day 3 of her cycle showed menstrual endometrium, 2 follicles measuring 7 mm mean diameter on each ovary, FSH 16.4 IU/l, LH 6.8 IU/l, and oestradiol 120 pmol/L. A repeat scan on day 6 of the cycle showed early triple layer endometrium (Endometrial thickness (ET) 4.7 mm), one 10 mm follicle on the right ovary, and a 10.5 mm on the left ovary. The following scan on day 9 showed triple layer endometrium (ET 7.4 mm), a 12.4 mm follicle on the right ovary and 11.9 mm follicle on the left. The oestradiol level was 613 pmol/l and LH 7.5 IU/l. On the morning of day 11 of the cycle the patient reported a strongly positive urinary LH test and felt that she might have surged the previous evening although the test was equivocal. A scan showed a triple layer endometrium 9.10 mm and a dominant follicle on the right side measuring 16.3 mm with very good peri-follicular blood flow with peak systolic velocity 19.6 cm/s. In view of this, oocyte retrieval was scheduled for later in the same day.

Transvaginal oocyte collection was attempted using a double lumen Vitrolife® follicle aspiration set 1.6 × 350 mm with 4 flushings of the follicle. Granulosa cells were observed in both the aspirates and flush but unfortunately no oocyte was identified. The patient gave agreement to another attempt the following morning and was given hCG 10000 IU subcutaneously. The following morning the ultrasound scan showed a regular round follicle in the

right ovary with clear contents measuring 11.3 mm (Fig. 1) which had very good peri-follicular blood flow with a peak systolic velocity of 27 cm/s (Fig. 2). 24 hours after hCG injection a further attempt at oocyte collection yielded an oocyte cumulus complex. Four hours post oocyte collection the cumulus cells were denuded using hyaluronidase (Sage, Cooper Surgical) and EZ Strip pipettes (RI UK Ltd) a metaphase-I oocyte was observed. This metaphase-I oocyte was transferred into Oocyte Maturation Media (Sage, Cooper Surgical, USA) for maturation in culture and checked after 4 hours. The oocyte had extruded the polar body and ICSI was performed on the resulting Metaphase-II oocyte 3/4 hours post PB observation. Fertilisation was confirmed by the presence of 2 pronuclei (Fig. 3). A 2-cell grade one embryo was transferred uneventfully on Day 2 under ultrasound guidance using Wallace SureView 23 cm (Smiths Medical International Ltd). A positive βHCG of 108 was detected 2 weeks after the ET and a viable clinical pregnancy with clear foetal heartbeat was seen on ultrasound 2 weeks later.

Discussion

This case raises important issues regarding the management of patients undergoing natural cycle IVF. The first issue is why we recommended natural cycle IVF to this patient. In women with critically low ovarian reserve, natural cycle IVF has shown favourable results compared to stimulated IVF. The main advantage of natural cycle IVF in these circumstances is that natural selection of the leading follicle will result in a higher quality oocyte without the adverse effects of high oestrogens on the endometrium. Another issue in a natural cycle is when to schedule the oocyte collection when the

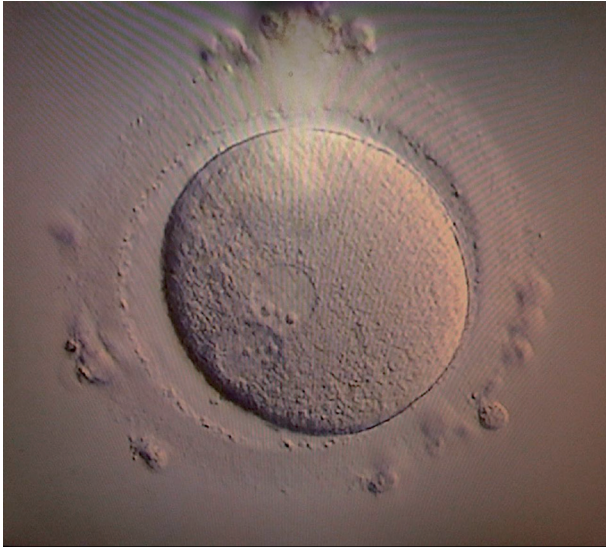

Fig. 3. — 2PN zygote from double rescue egg retrieval and IVM.

urine LH test is positive. In this case we assumed that the urine test had been positive on the evening prior to day 11. This was reinforced by the strongly positive urine LH test on the morning of day 11 and the strong peri-follicular blood velocity which was suggestive of impending ovulation. We now assume that the first attempt at egg collection which was performed 18 hours after the presumed positive urine test was performed too early but we were anxious to avoid follicular rupture before the attempt was made. Two factors influenced the decision to repeat the OR procedure. Firstly granulosa cells had been identified in the aspirate which indicated the likelihood of a cumulus being present but adherent to the wall of the follicle. The second was the strong peri-follicular flow which had an even higher velocity to that found the previous day. The implication from this was that angiogenesis was still continuing and the prospects of obtaining an oocyte on repeat OR was reasonably good. Peri-follicular velocity is directly correlated with oocyte retrieval and the quality of oocyte (Nargund et al., 1996). In this case, the patient was warned that if the follicle had filled in with blood clot then no attempt would be made but fortunately the appearance of

the follicle gave hope that there was fluid to be aspirated. A final issue concerns what to do if an immature oocyte is obtained. It has been shown that IVM of Metaphase I oocytes over a short time period can increase the number of embryos in stimulated cycles (Li et al., 2011); however we believe that in any unit offering natural cycle IVF the laboratory should be in a position to offer IVM to “rescue” immature oocytes and offer an opportunity for a successful outcome.

Natural cycle IVF is an increasingly important part of our daily practice in reproductive medicine. Precise selection of the suitable candidates for such treatment and accurate guidance through the treatment with close ultrasound and biochemical monitoring together with profound knowledge of follicular developmental physiology is the cornerstone of obtaining successful results. In the case described here using the latest both ultrasound (Doppler) and laboratory technology we were able to avoid cancellation and achieved a successful outcome.

Acknowledgements

The authors would like to thank Dr. Martin Hrehorčák and Paul Wilson for their work and help with this case report.

References

- Ata B, Balaban B, Urman B: Embryo implantation rates in natural and stimulated assisted reproduction treatment cycles in poor responders: RBM Online. 2008;17:207-12.
- Li M, Li Y, Ma SY et al. Evaluation of the developmental potential of metaphase I oocytes from stimulated intracytoplasmic sperm injection cycles. *Reprod Fertil Dev.* 2011; 23:433-7.
- Nargund G, Doyle PE, Bourne TH et al. Ultrasound derived indices of follicular blood flow before HCG administration and the prediction of oocyte recovery and preimplantation embryo quality. *Hum Reprod.* 1996;11:2512-7.
- Nargund G, Waterstone J, Bland J et al. Cumulative conception and live birth rates in natural (unstimulated) IVF cycles. *Hum Reprod.* 2001;16:259-62.
- Nargund G, Frydman R: Towards a more physiological approach to IVF. *Reprod Biomed Online.* 2007;14:550-2.
- Schimberni M, Morgia F, Colabianchi J et al. Natural-cycle in vitro fertilization in poor responder patients: a survey of 500 consecutive cycles. *Fertil Steril.* 2009;92:1297-301.